

PHOTO QUIZ

An unusual finding on a chest X-ray

T.C. Kemper¹, M.C. Müller²

Department of ¹Anesthesiology and ² Intensive Care Medicine, Academic Medical Center, Amsterdam, the Netherlands

Correspondence

T.C. Kemper - t.kemper@amc.uva.nl

A 72-year-old female was admitted to the ICU after an emergency angiography for an intracranial haemorrhage, as a complication of an uneventful elective aneurysm coiling of the anterior cerebral artery. Her past medical history consisted of hypertension, non-insulin dependent diabetes and hypothyroidism. On admission to the ICU a routine chest X-ray was ordered, which showed an unusual contour in the right hemithorax.

What is your diagnosis?

Answer

You will find the answer on page 28 of this issue.

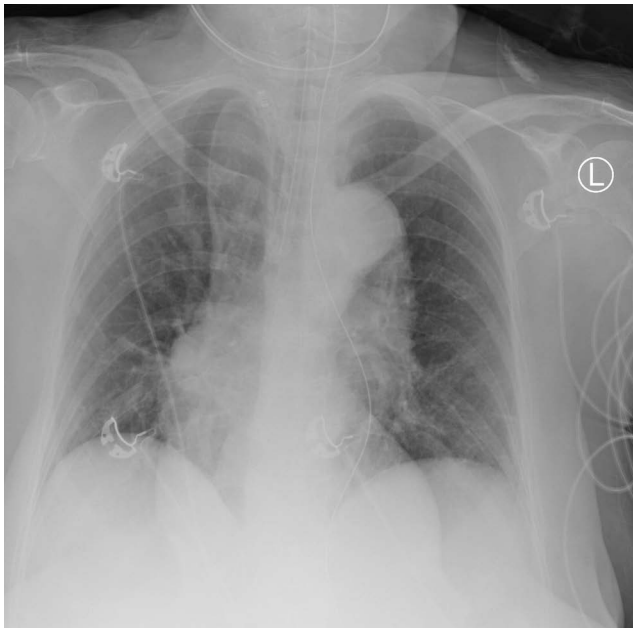


Figure 1. Chest x-ray

